

Outpatient Management of Malignant Pleural Effusions with Small-Bore, Tunneled Pleural Catheters

Ali I. Musani Andrew R. Haas Luis Seijo Mary Wilby Daniel H. Sterman

Interventional Pulmonology Program, Division of Pulmonary, Allergy and Critical Care Medicine, University of Pennsylvania Medical Center, Philadelphia, Pa., USA

For editorial comment see p. 549

Key Words

Pleural catheter · Malignant pleural effusion · Pleurodesis · Outpatient

Abstract

Background: Malignant pleural effusions (MPEs) can produce significant respiratory symptoms and diminished quality of life in patients with terminal malignancies. Control of MPEs to palliate respiratory symptoms can be performed via several different approaches. Ideally, a minimally invasive procedure to control MPEs and to provide relief of respiratory symptoms would be optimal. **Objective:** To ascertain if control of MPEs can be achieved by outpatient management via a small-bore pleural catheter (PC) without the need for sclerosing agents. **Methods:** Retrospective chart analysis of 24 patients after outpatient insertion of PCs for recurrent, symptomatic MPEs followed by frequent home drainage of pleural fluid to relieve respiratory symptoms. **Results:** Symptomatic relief of respiratory symptoms was achieved in 100% of patients, while pleurodesis was

achieved in 58% of patients in a mean of 39 days. Five patients (6 PCs) expired with the catheters in place. In these patients, all catheters remained in position and functional until the patients ultimately died from non-pleural disease progression. No major complications occurred during insertion of the catheter. Late complications included localized cellulitis and bacterial superinfection in three patients and tumor growth at the catheter site in one patient. **Conclusions:** The PCs used in the present study provided an effective modality not only to alleviate respiratory symptoms associated with MPE, but also to achieve pleurodesis in 58% of our patients. These catheters may provide a significantly less invasive outpatient approach to the palliative management of MPEs.

Copyright © 2004 S. Karger AG, Basel

A.I.M. and A.R.H. contributed equally to the production of this paper.

Introduction

Malignant pleural effusions (MPEs) complicate many advanced malignancies and can elicit significant dyspnea, cough and chest pain. Bronchogenic carcinoma accounts for over one third of MPEs, followed by breast cancer and lymphoma, and less commonly mesothelioma, ovarian cancer and gastric and esophageal cancer [1–3]. In gener-

KARGER

Fax +41 61 306 12 34
E-Mail karger@karger.ch
www.karger.com

© 2004 S. Karger AG, Basel
0025-7931/04/0716-0559\$21.00/0

Accessible online at:
www.karger.com/res

Ali I. Musani, MD, Associate Director
Interventional Pulmonology Program, Pulmonary, Allergy and Critical Care Division
3600 Spruce Street, Hospital of the University of Pennsylvania
Philadelphia, PA 19104-4283 (USA)
Tel. +1 215 615 0786, Fax +1 215 614 0518, E-Mail amusani@mail.med.upenn.edu

al, MPEs portend a poor prognosis with a mean length of survival of 6 months [4]. Consequently, a reasonable therapeutic goal in patients with MPEs would be to provide palliative relief of discomforting respiratory symptoms.

Several different techniques are available for the management of MPEs. While needle thoracentesis is required to obtain a diagnosis, it is frequently insufficient to treat recurrent MPEs due to the rapidity of symptomatic fluid reaccumulation and patients' desire to avoid repeated thoracenteses. In fact, one study reported symptomatic fluid reaccumulation within 4.2 days of initial therapeutic thoracentesis [5]. Therefore, palliative therapy for MPEs has focused not only on draining the pleural fluid, but also on achieving sclerosis of the pleural space to prevent reaccumulation of symptomatic MPEs. The American Thoracic Society defines complete or effective pleural sclerosis as 'long-term relief of symptoms related to a pleural effusion, with absence of fluid reaccumulation on chest radiographs until death' [6].

The most common technique to attain pleural symphysis in MPEs involves inpatient chest tube drainage followed by chemical pleurodesis with various agents such as talc, bleomycin, quinacrine or doxycycline [2, 4, 7]. Pleural symphysis has been demonstrated in up to 80–90% of talc slurry pleurodeses; however, not all patients are optimal candidates for this approach [7–9]. More invasive modalities to achieve pleural symphysis include medical thoracoscopy or video-assisted thoracoscopic surgery with mechanical pleural abrasion and/or chemical sclerosis [8, 10–16]. Although the aforementioned techniques may achieve pleurodesis with high degrees of success, they can entail significant morbidity, including prolonged inpatient hospitalization, limited mobility from the pleural drainage apparatus, fevers from pleural inflammation and significant pain from the chest tube, surgical incision and/or the sclerosing agent. Since many patients with MPEs have already experienced significant morbidity from chemotherapy and/or radiation therapy, it would be ideal to minimize hospitalization and patient discomfort in the process of relieving respiratory symptoms and controlling fluid reaccumulation.

For these reasons, the utilization of small-bore catheters for prolonged inpatient and/or outpatient drainage of MPEs has been advocated in a number of case reports [17–20]. These early descriptions contributed to the development of a small-bore, flexible, tunneled pleural catheter (PC) that allows for periodic home drainage of MPEs. Several studies have demonstrated that PCs are as effective as chest tubes when used for chemical pleurodesis, with significantly less pain, cost and hospitalization [21–




Fig. 1. **a** PC with a one-way valve at the distal end. **b** Disposable vacuum bottle and drainage tubing for insertion into the one-way valve of the PC.

26]. In addition, tunneled PCs have proven effective in the management of refractory MPE in patients who cannot achieve pleurodesis because of 'trapped lung' syndrome [27]. These catheters may significantly change the management of MPEs, as they can be inserted on an outpatient basis with minimal postprocedure discomfort, thereby obviating the need for hospitalization. Furthermore, patients can drain the MPE at home based on their symptoms, and potentially achieve pleurodesis without significant pain or hospitalization. We report here on outpatient insertion and usage of indwelling PCs to achieve symptomatic relief and, in the majority of cases, effective pleurodesis in a series of 24 patients (27 PCs) with symptomatic MPEs.

Patients and Methods

Patient Population

We performed a retrospective analysis of 24 patients who underwent outpatient PC placement for recurrent symptomatic MPE between July 2001 and June 2002 in the Interventional Pulmonology Program of the University of Pennsylvania Medical Center. Sixteen women and eight men, ranging in age from 47 to 89 years with a mean age of 62.7 years, were included in this study (table 1). The underlying malignancies were as follows: breast (11), lung (5), colon (1), mesothelioma (3), renal (1), melanoma (1) and adenocarcinoma of unknown primary (2). All patients had symptomatic MPEs and were selected for PC insertion based on the following criteria: (1) advanced primary malignancy, (2) predicted life expectancy of at least 3 months, (3) symptomatic relief of dyspnea or other symptoms after prior thoracentesis and (4) radiographic evidence of an accessible, free-flowing, pleural effusion.

Catheter Placement

The indwelling PC (Pleurx® Catheter, Denver Biomedical, Golden, Colo., USA) used in the present study is a 66-cm-long, 15.5-Fr flexible silicone rubber catheter with fenestrations along the distal 24 cm. A valve at the proximal end prevents fluid and/or air from

Table 1. Demographics and details of outcome and complications of individual patients

Patient	Age years/sex	Diagnosis	PC duration, days	Outcome	Follow-up	Comments
1/BB	53/F	unknown primary	14	pleurodesis	alive no recurrence	
2/DR	69/M	lung cancer	55	pleurodesis	alive no recurrence	
3/MV	56/F	breast cancer PC 1 (left) PC 2 (right)	15 21	patient expired	expired with functional PC	
4/MAF	56/F	breast cancer	49	patient expired	expired with functional PC	trapped lung
5/AH	58/F	breast cancer	7	pleurodesis	no recurrence before death	
6/DP	68/F	breast cancer	31	patient expired	no recurrence before death	
7/EF	61/F	colon cancer	15	partial pleurodesis	no intervention before death	small reaccumulation
8/IS	69/M	lung cancer	78	pleurodesis	no recurrence before death	
9/HP	82/M	mesothelioma	24	pleurodesis	alive no recurrence	
10/WS	52/M	malignant melanoma	21	patient expired	expired with functional PC	
11/CB	53/F	breast cancer PC 1 (right) PC 2 (right)	55 32	failed pleurodesis PC working	expired with functional bilateral PCs	reaccumulation
12/MS	64/F	breast cancer	21	pleurodesis	alive no recurrence	small loculations
13/EM	59/F	lung cancer	21	pleurodesis	no recurrence before death	cellulitis of PC site
14/GM	62/M	renal cancer PC 1 (right) PC 2 (left)	63 29	pleurodesis discontinued	no recurrence on either side before death	empyema
15/LW	61/F	breast cancer	44	pleurodesis	alive no recurrence	
16/LK	49/F	breast cancer	63	talc pleurodesis	no recurrence before death	cellulitis
17/HD	89/M	mesothelioma	105	PC working	expired with functional PC	trapped lung
18/BC	58/F	lung cancer	85	pleurodesis	no recurrence before death	
19/ED	78/M	lung cancer	21	patient expired	expired with functional PC	
20/PF	55/F	unknown primary	11	discontinued	alive no recurrence	cellulitis, empyema
21/GR	78/M	mesothelioma	18	discontinued	died, no intervention undertaken	empyema
22/HR	68/F	breast cancer	40	talc pleurodesis	no recurrence before death	
23/JO	52/F	breast cancer	46	PC working	alive with functional PC	
24/SR	47/F	breast cancer	16	PC working	alive with functional PC	

exiting/entering the catheter until a matching drainage line has accessed it. A polyester cuff is situated approximately 14 cm from the proximal end and lies within a subcutaneous tract (see below) to decrease bacterial translocation and to anchor the catheter in position (fig. 1).

PC insertion was performed on an outpatient basis at the Penn Lung Center under the supervision of the Director of Interventional Pulmonology. PCs were placed in a bronchoscopy suite under local anesthesia with 1% lidocaine using intravenous midazolam and/or

fentanyl for conscious sedation as needed. Blood pressure, oximetry and cardiac monitoring were performed throughout the procedure. A modified Seldinger technique was employed to insert a PC in the midaxillary line after standard needle thoracentesis localized the pleural effusion. A flexible wire was passed through the needle into the thorax, and a 1.5-cm horizontal incision was made at this site. A second horizontal incision was made 5 cm inferiorly with a subcutaneous tunnel created between the incisions by dissecting the skin from the underlying connective tissue. A trocar guided the PC

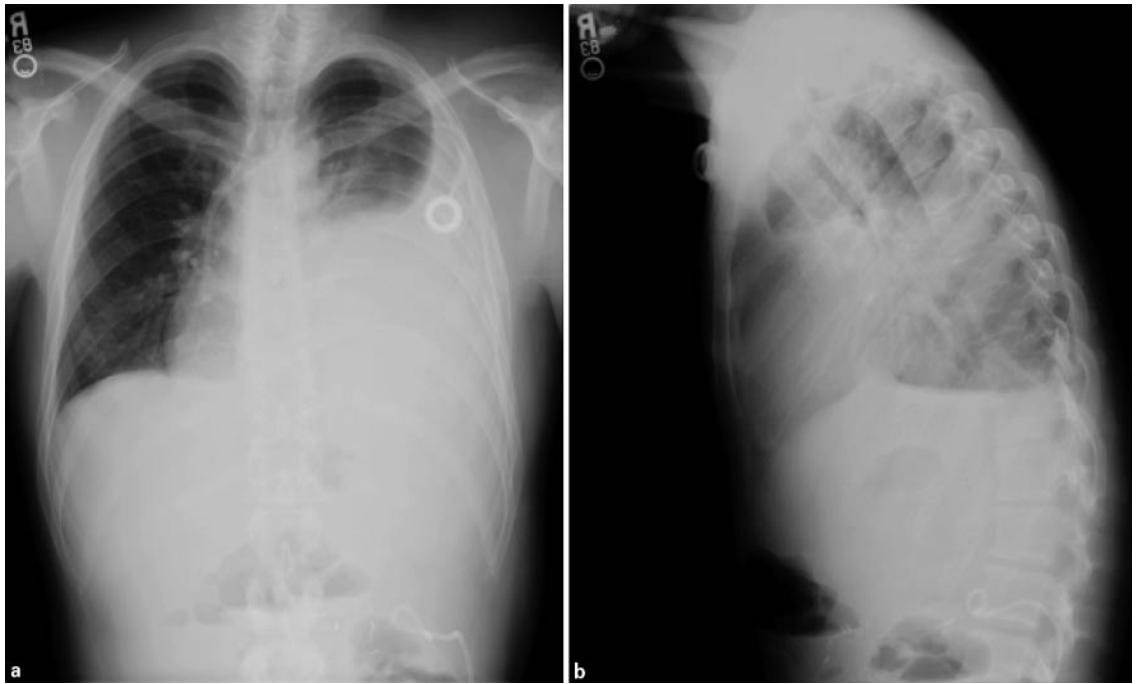


Fig. 2. PA (a) and lateral (b) chest radiograph of a patient with left MPE prior to the insertion of the PC.

through the subcutaneous tunnel, and the polyester cuff was placed 1 cm above the inferior incision. A dilator with a peel-away sheath was placed over the wire and directed inferoposteriorly into the thorax. The dilator was removed, the PC was threaded through the sheath into the thorax, and the sheath was removed. Incisions were closed with interrupted nonabsorbable sutures, and the catheter was secured to the skin. After insertion, 1,000–1,500 ml of pleural fluid was drained immediately, and a chest radiograph was obtained to ascertain catheter position and to rule out a pneumothorax.

Detailed written and oral instructions for home catheter care and drainage were provided to patients and their caregivers. Visiting nurse services were employed initially to provide additional teaching and to assist with catheter care and drainage. Home pleural drainage of up to 1,000 ml on a daily basis was performed with the assistance of trained visiting nurses. Patients were reevaluated in the University of Pennsylvania Medical Center Pulmonary Outpatient Practice weekly for the first 2 weeks, and then as clinically indicated. At subsequent follow-up visits in the Penn Lung Center, the patients were assessed subjectively for the presence of dyspnea, chest discomfort and exercise tolerance, and objectively for supplemental oxygen requirements. The patients were also evaluated for pulmonary and PC-related complications. Measurements of pulse oximetry, blood pressure, heart rate, respiratory rate and weight were performed at each follow-up visit. Periodic chest radiographs and CT scans were performed when indicated. A thorough record of both subjective and objective evidence of improvement and/or deterioration was maintained. Once PC output diminished to less than 50 ml on 3 consecutive days, the PC was removed in the Pulmonary Outpatient Practice under local anesthesia without the need for sedation. Once the PC was removed, the patients were followed periodically in the Inter-

ventional Pulmonology outpatient practice for the recurrence of symptoms or effusion. Chest radiographs following catheter removal were performed when indicated by physical examination and interval history.

Results

Twenty-four patients presented to the Outpatient Interventional Pulmonary Practice for evaluation and treatment of recurrent, symptomatic MPE following standard needle thoracentesis (fig. 2). Twenty-seven catheters were placed in these 24 patients during the time period of the study (fig. 3, 4). Three patients underwent bilateral PC insertion, and one patient had sequential placement of two ipsilateral PCs. All PCs were inserted in an outpatient setting, and each patient was discharged home the same day.

Five patients (6 PCs) in this analysis expired during the period of this study. In 4 of these patients (5 PCs), the catheter was in place and functional at the time of death. The 5th patient developed cardiac tamponade physiology from a large pericardial effusion, which required an emergent thoracotomy to place a pericardial window. During this procedure, the PC was replaced by a standard chest tube. This patient expired several days later. The mean duration of PC indwelling time for these 5 patients prior

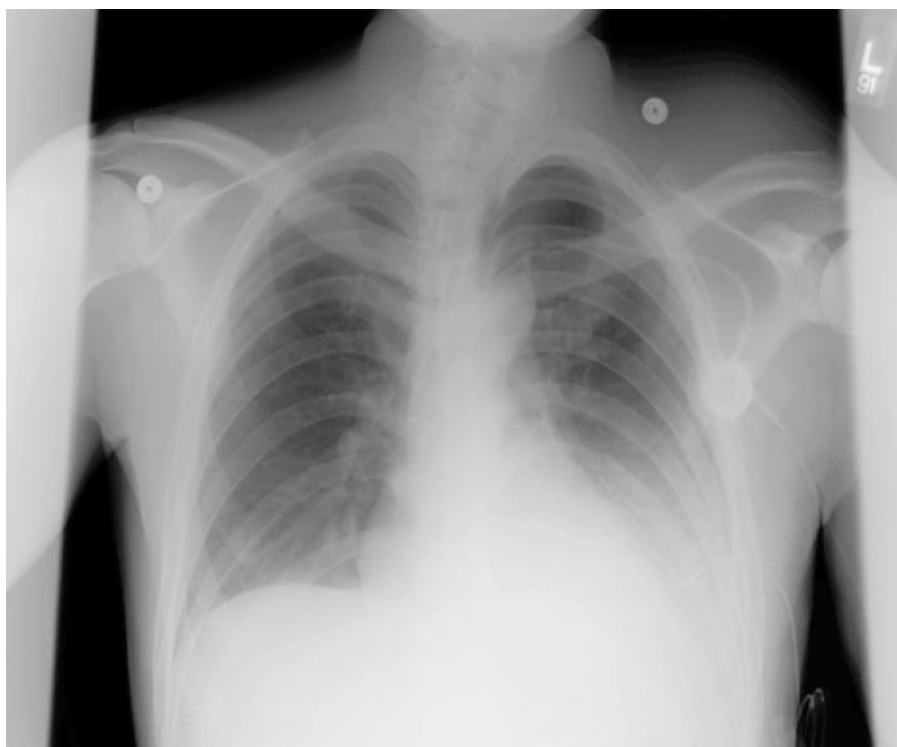

Fig. 3. AP radiograph of the same patient as in figure 2 after the insertion of a PC and first drainage of 1,200 ml of bloody effusion. The PC can be seen first along the diaphragm and then along the left heart border.

to death was 26.3 days (range 15–49 days). None of these patients died from respiratory failure related to reaccumulation of the MPE.

Nineteen patients (21 PCs) survived either to the time of PC removal or to the time of this analysis. Ten patients (53%) achieved effective pleural symphysis by using daily PC drainage. The mean duration of time required to achieve pleurodesis by PC-directed MPE drainage was 39 days (range 7–85 days). One patient achieved partial pleurodesis 15 days after PC placement. Although complete pleurodesis was not achieved, the patient's symptoms improved and the PC was removed. Therefore, we were able to achieve *complete or partial* pleurodesis and symptomatic relief of MPEs in 11 of 19 patients (58%) without the insertion of a standard chest tube or the instillation of sclerosing agents. Four patients (4 PCs) had had functional PCs in place for a mean of 49.8 days (ranging from 16 to 105 days) at the time of this analysis. Most notably, all patients, including those who did not achieve complete or partial pleurodesis, experienced significant relief of respiratory symptoms after placement of the PC. None of the ten patients who achieved complete pleurodesis showed any evidence of MPE recurrence. The patient with partial pleurodesis ultimately expired due to causes unrelated to the minimal reaccumulation of pleural fluid.

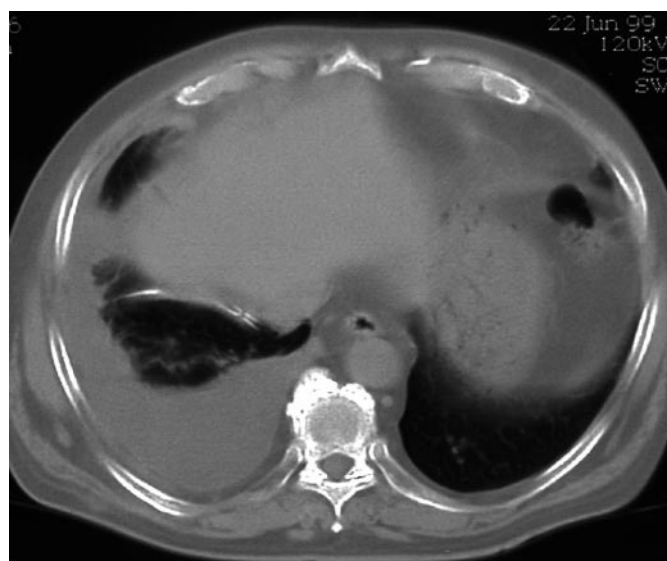

Fig. 4. Chest CT of a patient with a PC in place.

The PCs were placed without any major immediate complications such as pneumothorax or significant bleeding. Most patients required mild oral analgesia for several days after PC insertion, primarily related to pain associated with dissection of the subcutaneous tunnel. Several

minor complications were associated with the PCs (16%, 4/24 patients). One patient developed a localized, superficial cellulitis that was treated with oral antibiotics. Three patients developed bacterial seeding of the pleural fluid, 2 of whom responded well to discontinuation of the PCs and intravenous antibiotics, whereas the 3rd patient required removal of the PC followed by insertion of a standard chest tube and intravenous antibiotics.

Two patients underwent talc slurry pleurodesis due to large volume drainage even after 6–8 weeks of PC placement. One patient had a PC replaced ipsilaterally due to reaccumulation of the effusion several weeks after achieving presumed pleurodesis and discontinuation of the PC. Another patient developed extension of malignancy through the catheter tract resulting in tumor growth at the PC site. Finally, one patient required the sequential placement of two ipsilateral PCs after a subsequent, symptomatic, loculated effusion developed following insertion of the first PC. The second PC provided symptomatic relief and remained in place until the patient expired.

Discussion

The development of MPEs in advanced malignancies can cause significant morbidity and can lead to progressive respiratory failure and death. Adequate drainage of MPEs with subsequent pleural symphysis can provide significant palliation for these patients. Several approaches are available to provide palliation, including repeated thoracentesis, chest tube drainage with chemical pleurodesis, or medical thoracoscopy or video-assisted thoracoscopic surgery with chemical or mechanical pleurodesis. As mentioned previously, each of these modalities has its limitations, and a more effective and less invasive approach for treating MPEs in patients with terminal malignancies would be desirable.

We report herein our experience with the utilization of an indwelling PC to provide palliation for MPEs. Although previous studies have reported the effectiveness of PC chemical pleurodesis to be similar to that of standard chest tube chemical pleurodesis, to our knowledge, no prior report has described the role of PCs inserted and managed strictly on an outpatient basis for control of MPEs [21–26].

In our retrospective analysis of the 19 patients (21 PCs) who survived, 58% (11/19) achieved complete or partial pleural symphysis within a mean of 39 days, thereby allowing PC removal. In four additional patients, the PC remained functional with symptomatic relief of respiratory

distress, despite the inability to attain complete pleural symphysis. In fact, although complete or partial pleurodesis was achieved in only 58% of the patients, symptomatic relief of respiratory distress occurred in 100% of patients. Conceivably, we could have increased either our success rate or the rapidity of pleurodesis by instilling a sclerosing agent after a predefined period of outpatient drainage of the MPE failed to achieve pleurodesis. In fact, we performed successful talc slurry pleurodesis through the existing PCs in two of our patients. This decision was based on patient preference after symptomatic pleural fluid continued to reaccumulate even after 6–8 weeks of drainage.

In 4 of the 5 patients (6 PCs) who expired during the study, the PCs were in place at the time of death without pleurodesis having been achieved. It cannot be predicted if these patients would have achieved pleurodesis had their survival been prolonged (mean time to death following catheter insertion of 26 days for these patients vs. mean time to pleurodesis of 39 days in the surviving patients). Since the PCs were functional at the time of death, they provided relief of respiratory symptoms via a minimally invasive outpatient technique in a group of terminally ill patients.

The complications related to the placement and maintenance of the catheters were minimal. No adverse events occurred during PC placement, and localized cellulitis, bacterial superinfection and incisional tumor growth occurred in a minority of patients. Each of these complications could be managed conservatively with either antibiotics, removal of the PC or additional antineoplastic therapy. In addition, two patients developed loculated pleural effusions while the PC was in position. In one of these patients, no further intervention was required. However, the other patient required a second PC to drain a large loculation, with subsequent symptomatic relief. This experience is not different from that seen with chest tube drainage and talc slurry instillation, in which loculations can also occur, occasionally requiring surgical intervention via video-assisted thoracoscopic surgery or open decortication.

Although MPEs can contain a significant amount of protein, no patient demonstrated evidence of protein malnutrition during the period of recurrent pleural fluid drainage reported in this study (although this was not an objective endpoint directly measured). This complication could be envisioned if pleurodesis was not attained and large-volume daily drainage was required over an extended period. Furthermore, no patients developed reexpansion pulmonary edema with the PC as the quantity of fluid drained could be tightly regulated, unlike the situa-

tion often encountered with placement of chest tubes, due to the technical aspects of a larger portal of entry and rapidity of tube placement.

Several mechanisms can be proposed regarding how pleural symphysis is attained without the use of chemical or physical irritants. First, physical separation of the visceral and parietal pleural surfaces by an MPE prohibits pleurodesis until the two surfaces can appose one another. Daily drainage of the MPE may permit sufficient apposition of the visceral and parietal pleurae to allow for eventual pleural symphysis. Second, daily drainage of the MPE may remove protein, cellular debris or other factors within the MPE that may interfere with the ability of the visceral and parietal pleura to appose one another. Third, certain inflammatory mediators (interleukin-2, tumor necrosis factor-alpha or transforming growth factor-beta) potentially released by the pleural surfaces or tumor cells into the MPE may serve as endogenous sclerosing agents once the visceral and parietal pleura are apposed. Finally, the PC itself may act as a physical irritant to stimulate inflammatory responses and permit pleural symphysis.

A distinct advantage that PCs have over standard chest tube drainage with chemical pleurodesis relates to the decreased morbidity in patients who already have experienced possibly both surgical and medical therapy for their primary malignancy. Current American Thoracic Society consensus guidelines for MPE suggest an initial thoracentesis to establish a diagnosis of MPE, followed by standard chest tube drainage with subsequent talc slurry instillation. This approach requires an average of 3–4 days of inpatient hospitalization and is associated with significant pain, limited mobility and separation from the home environment. Although this approach is quite effective in treating MPEs [7–9], inpatient hospitalization is costly and can be distressing for patients and their families coping with terminal illness who likely have already experienced multiple hospitalizations and procedures related to their underlying malignancy. The significant cost differential between inpatient chest tube-mediated pleurodesis and outpatient pleurodesis with PCs was illustrated in a study by Putnam et al. [28]. These investigators performed a retrospective analysis of financial data from their single institution and demonstrated that 60 patients treated with outpatient PCs had early (7-day) mean charges of USD 3,391 (SD ± USD 1,753), compared with USD 7,830 (SD ± USD 4,497) for 68 patients treated in hospital with a chest tube ($p < 0.001$) [28].

Several limitations are inherent in the present study and in the use of PCs to manage MPEs. The relatively small sample size of 24 patients reflects our first year of

experience in managing MPEs on an outpatient basis using indwelling PCs. In evaluating our clinical experience with the PC, it was initially necessary to utilize a retrospective-type analysis, as we did not plan on conducting a prospective study a priori when we began this outpatient MPE management program. Moreover, we recognize a potential selection bias in the fact that the sickest patients may have been excluded from this analysis as they were likely admitted as inpatients for management of their MPEs. Furthermore, we acknowledge the lack of objective quantification of symptomatic improvement or deterioration according to standardized scales; however, we keep a thorough record of subjective changes (such as pain, dyspnea and exercise tolerance) at each visit in our outpatient records.

Many of these concerns and deficiencies will be answered by a new, National Cancer Institute-sponsored, multicenter, prospective clinical trial, in which we are a participating center. This National Cancer Institute protocol, CLB-30102, is a phase III randomized study of pleurodesis using a standard chest tube with talc slurry versus a small PC for the treatment of symptomatic unilateral MPEs. In this study, patients will be stratified according to inpatient status, underlying malignancy and concurrent systemic chemotherapy, and randomized to one of two treatment arms. Patients in arm 1 undergo placement of a standard pleural chest tube; within 36 h of chest tube placement, patients undergo pleurodesis comprising intrapleural administration of talc slurry. Patients in arm 2 undergo pleurodesis comprising placement of a PC followed by daily pleural drainage. A total of 530 patients (265 per treatment arm) will be accrued for this study within 3.5 years. Besides objective parameters such as radiographic results and oxygenation, quality of life and dyspnea will be assessed using validated instruments at baseline and then 7–14 and 30–37 days after treatment (PDQ/Cancer.gov database).

In summary, our analysis reported here suggests that implementation of PCs for home drainage of MPEs should provide a cost-effective, minimally invasive, outpatient approach to relieve respiratory symptoms and to achieve pleurodesis compared to current strategies for the management of MPEs. All of these advantages could potentially represent not only a significant cost saving, but also a more acceptable palliative approach to the management of MPEs. This study provides additional impetus to conduct the National Cancer Institute-sponsored randomized clinical trial comparing current recommended guidelines of chest tube drainage with talc slurry pleurodesis with the approach of outpatient PC-mediated MPE control.

References

- 1 Sahn SA: Malignant pleural effusions. *Clin Chest Med* 1985;6:113–125.
- 2 Hausheer FH, Yarbrow JW: Diagnosis and management of malignant pleural effusion. *Semin Oncol* 1985;12:54–75.
- 3 Lynch TJ Jr: Management of malignant pleural effusions. *Chest* 1993;103:385S–389S.
- 4 Ruckdeschel JC: Management of malignant pleural effusions. *Semin Oncol* 1995;22:58–63.
- 5 Anderson CB, Philpott GW, Ferguson TB: The treatment of malignant pleural effusions. *Cancer* 1974;33:916–922.
- 6 American Thoracic Society: Management of malignant pleural effusions. *Am J Respir Crit Care Med* 2000;162:1987–2001.
- 7 Rodriguez-Panadero F, Antony VB: Pleurodesis: State of the art. *Eur Respir J* 1997;10:1648–1654.
- 8 Viallat JR, Rey F, Astoul P, et al: Thorascopic talc poudrage pleurodesis for malignant effusions. *Chest* 1996;110:1387–1393.
- 9 Sahn SA: Pleural diseases related to metastatic malignancies. *Eur Respir J* 1997;10:1907–1913.
- 10 Colt HG: Thorascopic management of malignant pleural effusions. *Clin Chest Med* 1995;16:505–518.
- 11 LoCicero J 3rd: Thorascopic management of malignant pleural effusion. *Ann Thorac Surg* 1993;56:641–643.
- 12 Waller DA, Morrirt GN, Forty J: Video-assisted thorascopic pleuroctomy in the management of malignant pleural effusion. *Chest* 1995;107:1454–1456.
- 13 Yim AP, Chung SS, Lee TW, et al: Thorascopic management of malignant pleural effusions. *Chest* 1996;109:1234–1238.
- 14 Jensk R, Cagle JE, Milloy F, et al: Pleuroctomy in the treatment of pleural effusion due to metastatic malignancy. *J Thorac Cardiovasc Surg* 1963;46:322–330.
- 15 Young D, Simon J, Pomerantz M: Current indications for and status of decortication for ‘trapped lung.’ *Ann Thorac Surg* 1972;14:631–634.
- 16 Martin N, Bains MS, Beattie EJ: Indications for pleuroctomy in malignant effusion. *Cancer* 1975;35:734–738.
- 17 Leff RS, Eisenberg B, Baisden CE, et al: Drainage of recurrent pleural effusion via an implanted port and intrapleural catheter. *Ann Intern Med* 1986;104:208–209.
- 18 Van Le L, Parker LA, DeMars LR, et al: Pleural effusions: Outpatient management with pigtail catheter chest tubes. *Gynecol Oncol* 1994;54:215–217.
- 19 Zeldin DC, Rodriguez RM: Management of refractory malignant pleural effusions with a chronic indwelling pleural catheter. *Chest* 1991;100:87S.
- 20 Grodzin CJ, Balk RA: Indwelling small pleural catheter needle thoracentesis in the management of large pleural effusions. *Chest* 1997;111:981–988.
- 21 Putnam JB, Light RW, Rodriguez RM, et al: A randomized comparison of indwelling pleural catheter and doxycycline pleurodesis in the management of malignant pleural effusions. *Cancer* 1999;86:1992–1999.
- 22 Clementsen P, Evald T, Grode G, et al: Treatment of malignant pleural effusion: Pleurodesis using a small percutaneous catheter. A prospective randomized study. *Respir Med* 1998;92:593–596.
- 23 Marom EM, Patz EF Jr, Erasmus JJ, et al: Malignant pleural effusions: Treatment with small-bore-catheter thoracostomy and talc pleurodesis. *Radiology* 1999;210:277–281.
- 24 Parker LA, Charnock GC, Delany DJ: Small bore catheter drainage and sclerotherapy for malignant pleural effusions. *Cancer* 1989;64:1218–1221.
- 25 Patz EF Jr, McAdams HP, Erasmus JJ, et al: Sclerotherapy for malignant pleural effusions: A prospective randomized trial of bleomycin vs. doxycycline with small-bore catheter drainage. *Chest* 1998;113:1305–1311.
- 26 Seaton KG, Patz EF Jr, Goodman PC: Palliative treatment of malignant pleural effusions: Value of small-bore catheter thoracostomy and doxycycline sclerotherapy. *AJR Am J Roentgenol* 1995;164:589–591.
- 27 Pien GW, Gant M, Washam C, Sterman DH: Use of an implantable pleural catheter for ‘trapped lung’ syndrome in patients with malignant pleural effusion. *Chest* 2001;119:1641–1646.
- 28 Putnam JB Jr, Walsh GL, Swisher SG, Roth JA, Suell DM, Vaporciyan AA, Smythe WR, Merriman KW, DeFord LL: Outpatient management of malignant pleural effusion by a chronic indwelling pleural catheter. *Ann Thorac Surg* 2000;69:369–375.